

ADVANCED DIABETIC RETINOPATHY DETECTION WITH THE R-CNN: A UNIFIED VISUAL HEALTH SOLUTION

VALLURI SRI SRAVYA ^a, PARVATHANENI NAGA SRINIVASU ^{b,c}, JANA SHAFI ^d,
WALDEMAR HOŁUBOWSKI ^e, ADAM ZIELONKA ^{e,*}

^aDepartment of Computer Science and Engineering
Prasad V Potluri Siddhartha Institute of Technology
Kanuru, Vijayawada, 520007, Andhra Pradesh, India

^bDepartment of Computer Science and Engineering
Amrita School of Computing
Amrita Vishwa Vidyapeetham, 522503, Andhra Pradesh, India

^cDepartment of Teleinformatics Engineering
Federal University of Ceará
100 Pres. Kennedy, 60455-970, Fortaleza, Brazil

^dDepartment of Computer Engineering and Information
Prince Sattam bin Abdulaziz University
11991, Wadi Alldawasir, Saudi Arabia

^eFaculty of Applied Mathematics
Silesian University of Technology
Kaszubska 23, 44-100 Gliwice, Poland
e-mail: adam.zielonka@polsl.pl

Diabetic retinopathy (DR) can cause blindness and vision impairment. This degenerative eye condition may lead to an irreversible vision loss. The prevalence of vision impairment and blindness caused by DR emphasizes the critical need for better screening and therapy measures. DR aetiology involves persistent hyperglycemia-induced microvascular abnormalities, oxidative stress, inflammatory reactions, and retinal blood flow changes. Common screening methods for retinal issues include fundus photography, OCT, and fluorescein angiography. For those with diabetic macular edema (DME), it is a common cause of vision loss. Our goal is to develop an automated, cost-effective method for identifying diabetic retinal disease specimens. This study introduces a faster R-CNN method for detecting and classifying DR lesions in retinal images. Those are classified across five different classes. An extensive analysis of 88,704 images from a Kaggle dataset indicates the efficiency of the proposed model, with a reasonable accuracy of 98.38%. The proposed method is robust in disease localization and classification tasks and it has outperformed other existing studies in DR recognition. On evaluating cross-datasets in Kaggle and APTOS, the model has yield better results during training and testing phases.

Keywords: disease diagnosis, diabetic retinopathy, convolutional neural networks.

1. Introduction

The retina comprises several layers: the inner limiting membrane acting as a barrier between the retina's interior and intraocular body; the layer of nerve fibers composed

of the terminals of ganglion cells in the retina; the layer of ganglion cells; the plexiform layer inside; the nuclear interior; the plexiform outer layer; the nuclear outermost layer. The rods and cones (photoreceptor layer) consists of the inner and outer photoreceptor segments. The retina is fed by a layer called the retinal pigment epithelium.

*Corresponding author

Diabetes is a medical condition that arises from having elevated blood glucose levels, sometimes referred to as blood sugar. Diabetic retinopathy (DR) is an eye condition triggered by diabetes. Typically, it begins by affecting the blood vessels in the retina's deepest layers, especially the inner nuclear and inner plexiform layers. The outer layers may get damaged as the condition worsens. Inflammation to the blood vessels in the retina, the tissue that senses light in the back of the eye, causes this lethal eye ailment. The retina's blood vessels might weaken with time and leak fluid or blood, resulting in swelling and the development of deposits (Fayyaz *et al.*, 2023). On the surface of the retina, abnormal blood vessels might develop under specific conditions, further impairing vision. For diabetics, early detection and intervention are essential to preventing severe visual damage and blindness.

Based on data from the IDF diabetes atlas (Sebastian *et al.*, 2023), about fifty million individuals worldwide have been diagnosed with the condition. By 2045, this sum is anticipated to rise to 700 million. It is a problem for world health. By 2040, DR will affect one in three diabetic people, according to the IDF diabetes atlas. Damaged blood vessels behind the retina are a sign of diabetic retinopathy. The World Health Organisation (WHO) (Ramanathan, 2017) estimates that a total of 422 million individuals worldwide suffer from DR. That figure is expected to rise to epidemic proportions over the next several decades. Globally, approximately 425 million DR patients were registered in 2017, and by 2040, that number is expected to rise to 642 million. Within 20 years after the onset of their diabetes, 60% of people with type 2 diabetes and those with type 1 diabetes develop DR (IDF, 2024). DR is a costly condition. The total direct cost of treating DR in Australia over 30 years was AUS \$4.8 billion, according to the national study AusDiab (Solomon *et al.*, 2017).

In order to address the vascular and neurodegenerative elements of diabetic retinopathy, current treatment approaches focus on damage to both the interior and exterior layers of the retina. Intravitreal injections of anti-vascular endothelial growth factor (anti-VEGF) medications and laser photocoagulation, which mostly affects the inner layers of the retina, are commonly used in the early phases of treatment for retinal neovascularization and macular edema. If neurodegenerative alterations in the outer retinal layers have already progressed, these therapies may not be very effective in maintaining visual function. By encouraging the survival of retinal neurons and regaining photoreceptor function, novel treatment approaches that target neuroprotection and retinal regeneration show promise for tackling the difficulties related to maintaining vision in diabetic retinopathy. Nevertheless, converting these experimental methods into clinically effective

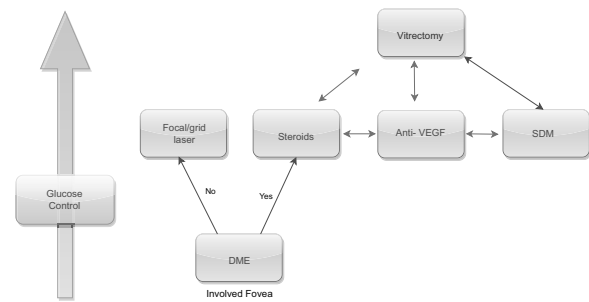


Fig. 1. DME structure in diabetic retinopathy.

treatments remains a significant hurdle, requiring further research and development efforts.

Diabetic retinopathy, a potentially blinding condition, can affect both type 1 and type 2 diabetics. It is a major contributor to visual impairment and, in severe cases, blindness. As the number of persons receiving type 2 diabetes diagnoses is rising, or is expected to become more common in the next decades. To identify DR and establish its stage, examining the presence or absence of several lesions is necessary. There are a variety of lesions that may be found in the eye, including microaneurysms, superficial retinal hemorrhages, exudates, intraretinal hemorrhages, spots of cotton wool, and both soft and firm exudates. The majority of blindness in people with diabetic macular edema (DME) (Romero-Aroca *et al.*, 2016) occurs as a result of the disease. The macula swells or thickens in DME when the blood-retinal barrier (BRB) breaks down, permitting internal and sub-retinal fluid accumulation in the macula as depicted in Fig 1. DME can occur at any point during DR, resulting in visual vision distortion and decreased acuity. Almost half of all individuals with diabetic retinopathy will develop macular edema, also known as macula swelling. This condition may happen at any point in time. Visual impairments, from slight blurring to total blindness, may result from enlargement in the macula's central region.

As depicted in Fig. 1, the DME treatment is determined based on the fovea inclusion. At any point, blood pressure, cholesterol, and glucose levels must be under control. Retinal and vitreous disorders are treated surgically with a vitrectomy with the basic help of steroids. Throughout the treatments, specialists remove the vitreous layer and replace it with a new solution, such as SDM (subthreshold diode laser micropulse photocoagulation) and Anti-VEGF (vascular endothelial growth factor). The anti-VEGF drug helps in the reduction of DR by preventing the growth of the vessels. This therapy requires regular clinical injections of a specific condition, whereas the SDM treatment involves treatment for various retinal conditions. It allows us to specify the target of cell growth and stimulate the cellular

processes.

There are four distinct phases of DR as shown in Fig. 2:

- (i) micro-aneurysms (MA) develop during the first stage of mild non-proliferative retinopathy.
- (ii) mild non-proliferative retinopathy, where the blood veins in the retina get larger and more distorted as the illness progresses, finally diminishing their capacity to carry blood.
- (iii) severe non-proliferative retinopathy to make up for the decreased blood flow brought on by the blockage of additional blood vessels, the retina grows new blood vessels.
- (iv) proliferative diabetic retinopathy (PDR), the severe type of diabetic retinopathy, the retina's production of growth hormones leads the inner layer of the retina in vitreous gel to sprout new blood vessels that fill the eye.

Because newly formed blood vessels are brittle, they bleed and leak more than usual (Yasashvini *et al.*, 2022). Furthermore, the accompanying scar tissue may compress, resulting in retinal detachment and permanent visual loss. Blood often seeps into the vitreous, a jelly-like material found in the center of the eye. Vision loss results from injury to the optic nerve, which is responsible for transmitting inverted pictures from the eye to the brain across the blind spot. Furthermore, advances in artificial intelligence (AI) and deep learning (DL) algorithms have demonstrated tremendous possibilities in automated DR identification, expediting the screening process and increasing access to care. Current therapeutic strategies for DR focus on managing diabetes through glycemic control, blood pressure regulation, and lipid management. A computerized DR grading system identifies and assesses DR early, prompting a reference to an ophthalmologist. The value proposition of these systems is decreased labor for ophthalmologists, resulting in increased cost-effectiveness of analysis and therapy.

Diagnosing diabetic retinopathy can be done in two ways: by classification or by identification. DR is detected by binary classification (DR or normal retina). Classification of diabetic retinopathy involves recognizing and marking the afflicted areas along with the infection severity (mild, moderate, or severe) as given in Table 1. Loss of pericytes in the early stages of DR can cause the microvasculature to collapse because they physically envelop the microvasculature and support endothelial cells (Bergers and Song, 2005). Interfering with the interaction between pericytes and endothelial cells aggravated diabetes-induced microvascular dysfunction (Liu *et al.*, 2019). According to experimental research, hyperglycemia kills pericytes in vitro and in vivo. There




Fig. 2. Image representing various stages of diabetic retinopathy phases.

is a substantial and complex corpus of scientific studies on DR. Epidemiology, pathophysiology, diagnosis, treatment, and improving research techniques have all seen substantial studies in DR. The epidemiological influence of many demographic, geographical, and socioeconomic factors on the incidence and prevalence of DR is significant. Studies examine the reexamining between DR development and factors such as ethnicity, age, gender, and dietary and lifestyle decisions. Pathophysiological studies elucidate how damage to the retinal blood vessels resulting from elevated blood sugar levels might lead to DR. Current study interests include oxidative stress, inflammation, pathways, and advanced glycation end products.

As DR is a public health burden, current treatment standards, which include a laser, anti-vascular endothelial growth factor (VEGF) treatment, steroids, and vitrectomy, needs to be improved, and novel treatments must be investigated (Tomita *et al.*, 2021). Competent eye physicians or individuals without eye training may execute the stages involved in the examination of retinography samples, contingent upon the results associated with acquired sensitivity (SE) and specificity (SP). In general, automated software exhibits commendable performance in the diagnosis of diabetic retinopathy, achieving a specificity (SP) of approximately 95% and a sensitivity (SE) of approximately 80% (Kandel and Castelli, 2020). Lesions are depicted as regions of circulating fluids and blood in fundus retinal images. Bright lesions may be classified as crimson lesions.

Table 1. Characteristics and clinical implications of DR stages.

DR stages	Characteristics	Clinical implications
No DR	No observable signs of retinal damage	Baseline for diabetic people with no retinal damage
Mild DR	Microaneurysms might be present.	Possible signature of early diabetic retinopathy
Moderate DR	Greater quantity of microaneurysms in addition to more obvious retinal exudates and hemorrhages.	Increased probability of visual impairment and diabetic macular edema (DME)
Severe DR	Massive exudates and hemorrhages in the retina and spots made of cotton and wool	Timely intervention can prevent further visual deterioration
Proliferative DR	Neovascularization (a development of aberrant blood vessels); Furthermore, a higher chance of vitreous hemorrhage.	High chance of blindness and severe vision impairment

Microaneurysms (MCAs) and haemorrhage (HM) are examples of bright lesions, whereas soft and firm exudates are red lesions. It is feasible to discern both varieties of exudates present in luminous lesions (EX). The larger dots in dark red correspond to HM, while the smaller dots correspond to MCA. Soft EX, alternatively referred to as cotton fibre, manifests as airy, yellowish-white regions, while hard EX assumes the appearance of dazzling yellow spots.

The main contributions of our work are as follows:

- The development of a robust DR detection model that helps in identifying several levels of DR.
- The techniques and methodologies used have a border view amplification of early identification of the DR. The Fast R-CNN helps extract the required feature and classify the DR with a high resolution of image analysis.
- Throughout our research findings, we contributed to a higher level of accuracy in identifying the lesions when compared with other models of VGG19 and ResNet.

This paper is organized as follows: Section 2 overviews related work. Section 3 discusses various common methods and materials. Section 4 briefly describes the main DR datasets and the proposed methodologies. Section 5 reviews papers and results in classifying DR. Section 6 presents the discussion, while Section 7 presents open research questions. Finally, Section 8 concludes the paper.

2. Literature review

A computer-assisted diagnosis technique using medical imaging technologies like retinal images was proposed

by Carrera *et al.* (2017) to aid in the early detection of diabetic retinopathy. The study analyzed the automated classification of the grade of non-proliferative diabetic retinopathy (NPDR) present in the retinal images. This technique first includes image processing in order to identify the blood vessels, microaneurysms, and hard fluids. The support vector machine (SVM) classifier then utilizes these results as features. The proposed approach was tested on a database comprising 400 retinal images labeled according to the 4-grade scale of non-proliferative diabetic retinopathy. Results indicated a maximum sensitivity of 95% and a predictive capacity 94%, highlighting the method's efficacy in accurately classifying the diabetic retinopathy grades. Robustness analysis demonstrated the algorithm's ability to withstand the parameter changes while maintaining the performance.

The suggested approach starts by employing saliency detection to separate the noteworthy elements from the color images. After that, the structure tensor approaches are used to improve the local edge patterns and intensity fluctuations. Gradient descent is then used to segment the lesions in active contour approximation. To help with the categorization of DR severity, the segmented images are assessed to determine the ratio between the total contour area and the real contour area in the prescribed arc length. More specifically, characteristics from the 35,126-image Kaggle fundus image dataset are used to train and evaluate the VGG-19 deep neural network. The VGG-19 model has demonstrated a sensitivity of 82% and 96% of accuracy after being trained on features from the 20,000 images and evaluated on the 5,000 images. This method effectively automates the labeling and classification of DR grades, which has significant potential for enhancing the early diagnosis and management of diabetic retinopathy.

Kaur and Kaur (2022) revealed a critical need for

the efficiency of DR screening methods to mitigate vision loss. Automated retinal analysis emerged as a cost-reducing and time-efficient solution, reducing the burden of manual screening. This study proposed a comprehensive preprocessing approach, integrating pixel removal, optic disc elimination, and blood vessel extraction, followed by a feature extraction and classification using a K-nearest neighbor (KNN) classifier. Evaluation of the DIARETDB1 benchmark dataset showcases promising results, with 95% accuracy, 92.6% sensitivity, and 87.56% specificity achieved. The proposed scheme demonstrates the potential to accurately diagnose the DR severity levels by minimizing the computation time. Leveraging advanced image processing and machine learning techniques, this approach is more valuable in enhancing DR screening programs and preserving patient vision. Furthermore, the validation of diverse datasets is warranted to strengthen their applicability and efficacy in clinical settings.

Aziza *et al.* (2019) address the pressing need for DR detection as the leading cause of blindness among diabetic patients. Due to its asymptomatic nature, blood vessel segmentation is essential for the early identification and prevention of vision loss. The proposed automatic system leverages the segmentation of blood vessels and extraction of the geometric features for early DR detection from the color fundus images. Application of the Hessian matrix, the ISODATA algorithm, and active contours achieved robust blood vessel segmentation. Classification into normal (NO-DR) or DR is accomplished using the decision tree CART algorithm. Evaluation of the DRIVE and Messidor databases demonstrates impressive performance metrics, with an average sensitivity, specificity, and accuracy of 89%, 99%, and 96% for vessel segmentation and 91%, 100%, and 93% for DR classification, respectively. These results underscore the effectiveness of the proposed approach in early DR diagnosis, offering improved accuracy compared with the existing methods and aiding ophthalmologists in timely interventions.

Harun *et al.* (2019) address the challenge of accurately classifying the DR in fundus images which are often characterized by low contrast and blurriness. Leveraging artificial neural networks, specifically a multi-layered perceptron trained using the Levenberg–Marquardt algorithm and Bayesian regularization (BR), the research aims to differentiate between the images with and without signs of the DR. From the fundus images, which are used as neural network inputs, nineteen characteristics are retrieved. Through this analysis and evaluation with varying numbers of hidden nodes, it is revealed that the MLP trained with BR yields superior classification performance, achieving an accuracy of 72.11% in training and 67.47% in testing. This has surpassed the results obtained with the

LM algorithm. This finding underscores the potential of Bayesian regularization as a viable approach for enhancing the classification accuracy in artificial neural network models, offering insights that could benefit the future research in this domain.

Rakshitha *et al.* (2016) emphasized the importance of retinal images in identifying ocular disorders with an analysis of ailments like hypertension and diabetic retinopathy. Because of their poor dynamic range and gray-level contrast, these images present intrinsic problems that require a sophisticated image augmentation technique for better diagnosis of the results. This research improves the image using three new imaging transforms: wavelet, curvelet, and contourlet transform. The main goal is to thoroughly compare the three imaging transformations and illuminating how well they improve retinal images for diagnostic use. The research indicates that the contourlet transform outperforms wavelet and curvelet transforms in edge detection through this experimental analysis. Quantifiable metrics like the peak signal noise ratio (PSNR), which is comprised of statistics from sources like the Drive database and medical facilities, also support the evaluation.

Mohanty *et al.* (2023) have stated that there is a notable rise in the number of people with diabetic retinopathy, a serious eye disease brought on by elevated blood sugar levels that damages the blood vessels in the retina. This condition poses a significant threat to vision and may lead to blindness if not detected and treated early. In its initial stages, diabetic retinopathy often presents no symptoms, making it a challenging task to diagnose through routine eye examinations. As the disease progresses, patients may experience symptoms such as blurred vision, dark spots, or floaters in their vision. Early detection and timely intervention are also crucial in managing diabetic retinopathy and preventing severe vision loss. In order to avoid visual loss in those with prolonged diabetes, including younger people, it is critical to identify the DR as promptly as feasible.

Romeo *et al.* (2002) analyzed the sequence of events that are contributing to the heightened demise of the retinal vascular cells in diabetes. Their investigation explored both in-situ and in-vitro analyses of nuclear factor kappaB (NF-kappaB) activation. NF-kappaB, a regulator of the gene expression triggered by cellular stress, was the focal point of their study. Examination of the retinal capillaries from the diabetic eye donors revealed an elevated presence of NF-kappaB-positive pericyte nuclei compared with the nondiabetic donors, with endothelial cells exhibiting no such positivity. Increased microvascular cell apoptosis and the presence of acellular capillaries were specifically observed in the diabetic donors showcasing numerous NF-kappaB-positive pericytes.

Sorrentino *et al.* (2016) indicate a significant

microvascular complication of diabetes, gaining recognition as the world's leading contributors to working-age people legal blindness. The intricate development of this disease involves a web of overlapping molecular pathways, contributing to its multifaceted nature. The staging of the DR encompasses various severity levels, ranging from the non-proliferative to advanced proliferative forms. The progression of the DR unfolds through distinct changes involving specialized cell types, namely neural, vascular, and glial cells. Notably, before the clinically observable vascular complications, the impact of hyperglycemia and inflammation becomes the most evident in the retinal glial cells. These cells undergo a spectrum of structural and functional alterations, laying the groundwork for subsequent stages of the disease. By shedding light on these molecular and cellular dynamics, this review aims to enhance our understanding of the pathogenesis of DR, providing a foundation for future therapeutic strategies and interventions.

Sorrentino *et al.* (2016) identified DR as a common complication of diabetes that damages the retina and contributes significantly to global blindness. The early detection of a probable vision loss is critical, but it remains a complex procedure that requires competence in evaluating fundus images. A groundbreaking study was undertaken utilizing a deep learning model, which had been carefully trained and confirmed on a unique dataset. The model was then run in real-time at the Sindh Institute of Ophthalmology and Visual Sciences (SIOVS). The sophisticated model not only assessed the quality of test photographs, but also divided them into DR-positive and DR-negative categories. Over a five-week period, a total of 398 patients (232 male and 166 female) were screened, indicating the feasibility and efficacy of the methods used. The model demonstrated outstanding precision, with an accuracy rate of 93.72%. Clinical experts specialized in DR confirmed the high sensitivity and specificity, which were 97.30% and 92.90%, respectively. This finding offers a significant step forward in improving the early detection of DR by using deep learning skills to potentially revolutionize how this important diabetes complication is identified and treated.

Deep learning has grown in popularity in technological development, particularly in medical image analysis and classification, as noted by Alyoubi *et al.* (2020). Deep learning relies heavily on convolutional neural networks (CNNs), which have proven to be highly successful in a wide range of applications, including medical image processing. This paper investigates advanced approaches for identifying and categorizing DR in color fundus images using DL techniques. A comprehensive review of the available datasets tailored for color fundus retina images in the context of DR is represented. The article highlights the achievements of

recent state-of-the-art methods and addresses persistent challenges that warrant further investigation. By exploring the nexus of DL, medical imaging, and DR diagnosis, this review contributes to the ongoing discourse on refining diagnostic approaches and bringing in a new era of improved outcomes for at-risk individuals.

Oh *et al.* (2021) proposed the global population of visually impaired and blind individuals, due to which DR witnessed an alarming rise from 2.6 million in 2015 to an estimated 3.2 million in 2020. While high-income countries may experience a projected decrease in DR incidence, the imperative nature of early detection and treatment remains paramount for low-income and middle-income nations. The advent of DL techniques has opened new avenues, demonstrating that automated screening and grading of DR can significantly save time and workforce resources. Despite these advancements, most automatic systems predominantly rely on conventional fundus photography. This is a noteworthy limitation, as ultra-wide-field fundus photography can capture up to 82% of the retinal surface. Addressing this gap, our study introduces a diabetic retinopathy detection system grounded in ultra-wide-field fundus photography and leveraging DL capabilities.

Gupta and Chhikara (2018) described a persistent and systemic ailment that exerts its influence on various physiological organs, prominently affecting the delicate structures of the human retina. DR emerges as a consequential complication directly correlated with the presence of diabetes mellitus. Within the vast expanse of literature, an array of sophisticated machine-learning algorithms has been applied to detect DR. DR emerges as a consequential complication directly related to the presence of diabetes mellitus. This comprehensive review explores the diverse methodologies employed in detecting DR, centering on distinctive features such as the blood vessels, microaneurysms, and hemorrhages. The predominant dataset utilized across these empirical investigations consists of retinal fundus images, meticulously captured through cutting-edge imaging technology, specifically the fundus camera. This paper systematically dissects the DR detection process into two principal approaches: segmenting the blood vessels and identifying lesions. The empirical results from the various machine learning techniques undergo a rigorous comparative analysis based on the pivotal parameters, including sensitivity, specificity, area under curve (AUC), and accuracy. The discussion extends to a judicious evaluation of these outcomes concerning those obtained through the deep neural networks, culminating in a discerning determination of the most effective technique.

3. Proposed methodology

Diabetic retinopathy can be recognized by using a variety of techniques. The most popular is fundus photography, which involves taking images of the retina in the back of the eye to check for the symptoms of diabetes-related damage. A more involved treatment called fluorescein angiography entails injecting a fluorescent dye into the circulation and photo-graphing the retina as the dye travels through the blood vessels. Cross-sectional images of the retina are produced by optical coherence tomography (OCT) scans, which display the thickness and condition of each layer (Sakthi Sree Devi *et al.*, 2021). Artificial intelligence-based techniques have recently demonstrated their potential for automated retinal image detection (Rajesh *et al.*, 2023). These technologies provide an unbiased assessment and can improve screening accessibility, particularly in underserved or rural locations. The blood glucose levels and HbA1c tests are used to diagnose general diabetes problems and may also indirectly show the presence of retinopathy.

Optical and grid distortion, piece-wise affine transform, horizontal and vertical flip, random scale, shift from one color space to another, additive Gaussian noise, blurring, smoothing and sharpening, and gray scaling are some of the widely used techniques in image augmentation. This creates robustness by producing new images rather than simply oversampling the ones that are already present (Priyadharsini and Jagadeesh Kannan, 2023). By flipping, cropping, and padding, fresh data is created with the Keras Image Data Generator class, and the model was able to identify and generalize without any overfitting problem. The additional complex characteristics of the eye photos, including the microaneurysm, were exposed by image scaling and cropping. Retinal imaging has come a long way in the last few years. Among them, the most beneficial advancements have been ultrawide field imaging (UWF) (Patel *et al.*, 2020). This technique allows us to visualize a much greater area of the retina, allowing us to detect the lesions that were previously overlooked by the standard methods, namely in the peripheral retina. The control flow diagram of the proposed model can be seen in Fig. 3.

In the convolutional and fully connected layers of our neural network model, which was trained on 88,704 images, we employed L2 regularization to minimize overfitting. The loss function was modified to incorporate the L2 regularization, which is also known as the weight decay, by including a penalty term corresponding to the total of the squared weight values. By penalizing the excessive weights, this method lessens the likelihood that the model will become unduly complicated and lessens the likelihood that it would overfit the training set. L2 regularization helps to regulate the complexity of the

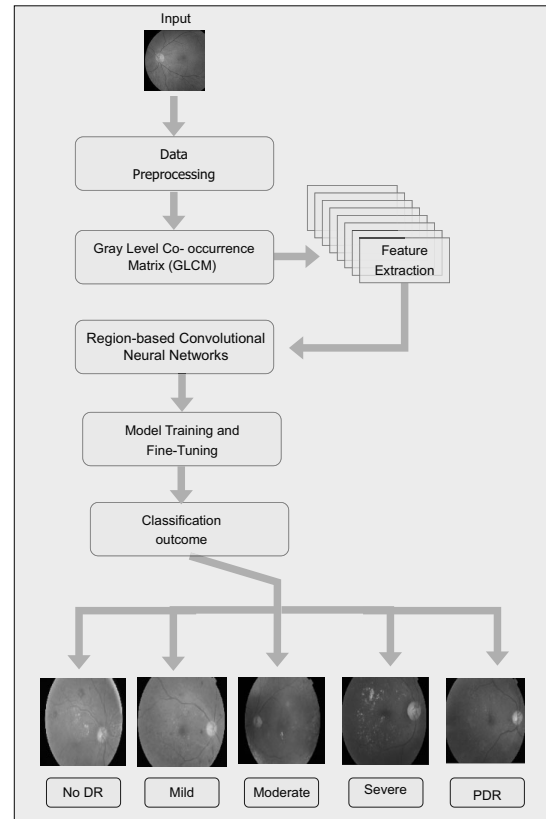


Fig. 3. Control flow of the proposed DR classification model.

kernels in the convolutional layers so that important patterns can be captured instead of the noise. Comparably, it guarantees that the network does not overly rely on any one of the characteristics in the fully linked layers, which improves in generalization (Hinton *et al.*, 2012). It can be represented as

$$L = \lambda \sum_{i=1}^n \omega_i^2, \quad (1)$$

where λ is the regularization parameter and ω_i are the model parameters.

3.1. Exploring diabetic retinopathy using R-CNNs.

Region-based convolutional neural networks (R-CNNs) have emerged as an important technique for the diagnose and classifying the DR. R-CNNs have the capacity to localize and categorize the objects within the images, which provides a comprehensive technique for identifying the distinctive lesions associated with the DR in the retinal imaging. In the case of diabetic retinopathy, R-CNNs first generate an area highlighting the prospective regions of the interest within retinal pictures that may include a disease-related lesions. These recommendations are then put into a convolutional neural network (CNN) for feature

extraction which determines the unique properties of DR lesions. The trained CNN then categorizes the each region proposed into appropriate categories, such as different phases of diabetic retinopathy (Albahli *et al.*, 2021).

This approach allows for the exact location and categorization of DR lesions which aids in accurate diagnosis and therapy planning. Furthermore, by fine-tuning pre-trained R-CNN models on huge datasets of annotated retinal pictures, researchers can improve the network's capacity to detect tiny alterations in DR lesions, increasing the diagnostic accuracy and efficacy in clinical settings. Overall, incorporating R-CNNs into the diabetic retinopathy diagnostic pipeline can improve screening efficiency, early diagnosis, and, ultimately, patient outcomes in managing illness.

3.2. Enhancing DR diagnosis through preprocessing and feature extraction. Preprocessing is crucial in preparing the retinal images for further algorithmic analysis. It typically involves removing noise, enhancing the contrast, and normalizing the lighting conditions across all images. It may also involve segmenting the images to highlight regions of interest, like the optic disc, blood vessels, and anomalies such as lesions or microaneurysms. It is critical to comprehend how computers interpret and store images. A computer can recognize the retinal picture by its pixel value. Feature extraction is obtaining more precise data about an image's composition, texture, color, and contrast (Naga Srinivasu *et al.*, 2024). The accuracy of the diagnosis system may be improved by selecting features. Images go through two processes: testing and training. Following input, the training image is verified. Using deep learning on a fundus picture, this study effectively diagnoses diabetes, and it may be used as one of the strategies to do so in the future.

A popular textural feature extraction technique in the field of medical image analysis, particularly diabetic retinopathy, is the gray-level co-occurrence matrix (GLCM). It includes the frequencies of adjacent pixel values in a picture, which aids in quantifying the geographic distribution and patterns of pixel intensities. With these data, details describing the image's texture may be extracted, which may help identify and diagnose diabetic retinopathy (Barburiceanu *et al.*, 2021). The calculation of GLCM involves figuring out how frequently a pixel with one intensity value occurs next to another pixel with a different intensity value in a given spatial relationship. The two-pixel intensity values are then represented by the rows and columns of the matrix, and the number of times the two-pixel values occur in the designated spatial connection is shown by the cell values. Numerous textural characteristics, including contrast, correlation, energy, and homogeneity, may be computed from this matrix. These calculations can yield important insights for the diagnosis of diabetic retinopathy. These

characteristics can be utilized to track the disease's course as well as to differentiate between retinas that are healthy and those that are incontinent. The elements of the GLCM for an image I of size $i \times j$ are

$$G(a, b) = \frac{G_{d_x, d_y}(a, b)}{\sum_{a=1}^n \sum_{b=1}^n G_{d_x, d_y}(a, b)}, \quad (2)$$

i.e., $G(a, b)$ is the normalized version of

$$G_{d_x, d_y}(a, b) = \sum_{x=1}^i \sum_{y=1}^j \begin{cases} 1 & \text{if } I(k, l) = a, I(i + d_x, k + d_y) = b, \\ 0 & \text{otherwise.} \end{cases} \quad (3)$$

3.2.1. Analysing DR with R-CNN based feature extraction. The use of R-CNNs to extract features for diabetic retinopathy is an enormous advance optimistically in medical image processing. DR is a prevalent outcome of diabetes and the major cause of visual loss globally. Early identification and diagnosis are critical to prompt intervention and treatment. The R-CNN, a mix of recurrent neural networks (RNNs) and CNNs provides a strong method for automatically extracting features from retinal images, assisting in correctly categorizing and diagnosing diabetic retinopathy. The process of extracting features occurs with the R-CNN model receiving retinal images as input (Das *et al.*, 2022). The network's convolutional layer (CL) extracts low-level visual information such as edges, textures, and forms from the input images as in Fig 4. These characteristics are then fed via recurrent layers, allowing the model to capture temporal dynamics and contextual information over numerous frames or patches of the image. This sequential processing enables the R-CNN to encode local and global information, improving its capacity to distinguish between healthy and sick retinal structures.

One of the primary benefits of R-CNN-based feature extraction is the ability to automatically learn discriminative features directly from data, eliminating the need for hand-made features or substantial pre-processing (Vankadaru *et al.*, 2023). This data-driven method allows the model to adapt to the numerous and complex properties of retinal images, enhancing its resilience and generalization performance across several datasets and patient groups. Furthermore, R-CNNs may be fine-tuned or pre-trained on large-scale datasets to improve feature extraction performance (Guleria *et al.*, 2023). In a nutshell, feature extraction using R-CNNs is a promising strategy for automated diabetic retinopathy diagnosis. By combining the characteristics of CNNs and RNNs, R-CNNs can successfully collect spatial and temporal

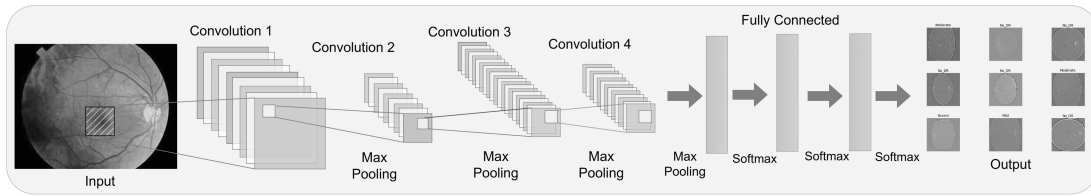


Fig. 4. R-CNN architecture used in DR classification.

data from retinal images, allowing for more accurate and timely identification of diabetic retinopathy and, ultimately, better patient outcomes. In the CL of the R-CNN (Ren *et al.*, 2017), the convolution procedure is described as follows:

$$I_k(i, j) = \sum_{m=-M}^M \sum_{n=-N}^N I(i+m, j+n) \cdot k(m, n). \quad (4)$$

Here I_k is the input image, M and N define the size of the kernel. The notation k denotes the convolutional kernel and the indexes i and j are the spatial coordinates of the output feature map. The hidden state at time step t in the recurrent layers is calculated using a ReLU activation function, as shown in the equation below.

$$h_t = \text{ReLU}(w_h x_t + U_h h_{t-1} + b_h), \quad (5)$$

where h_t denotes the hidden state at time step t . The input at time t is denoted by x_t , h_{t-1} . Moreover, w_h and u_h are weight matrices for the input and the hidden state, respectively. The symbol b_h denotes the bias value at the hidden layer h .

3.3. Lesion detection with R-CNNs in diabetic retinopathy analysis. Lesion identification in diabetic retinopathy research is an important step in achieving the early diagnosis and an appropriate disease treatment. R-CNNs have emerged as a potential solution to lesion identification in DR, using deep learning techniques to effectively identify and localize anomalies in the retinal images. The use of R-CNNs in DR analysis entails many critical processes. First, the R-CNN model is trained on a huge dataset of annotated retinal images with lesions, including microaneurysms, hemorrhages, and exudates explicitly labeled. During training, the R-CNN learns how to automatically extract the key characteristics from the retinal images and differentiate between the healthy and sick areas. The R-CNN architecture generally includes the CL for feature extraction, followed by the recurrent layers for collecting temporal relationships and contextual information between picture sequences (Vinayaki and Kalaiselvi, 2022). The aforementioned layout allows the model to successfully analyze the retinal images at various sizes and resolutions, making it easier to detect tiny lesions that might indicate the early stages of the DR.

By encompassing the recurrent layers into the network, R-CNNs can accurately simulate the sequential nature of retinal images, capturing the lesions' temporal progression across time. This temporal context is considered critical for discriminating between the transitory artifacts and chronic abnormalities, hence increasing the accuracy and reliability of the lesion diagnosis in DR. Additionally, R-CNNs may use transfer learning techniques to adapt the pre-trained models to specific DR datasets, which reduces the need for vast quantities of labeled data and speeds up the training process. Fine-tuning the pre-trained R-CNN models for DR-specific tasks allows them to learn the discriminative features essential to lesion identification in the retinal images, resulting in increased performance and generalization ability (Alwakid *et al.*, 2023). The detection of lesions is shown in Fig. 5.

3.3.1. Enhanced sensitivity and specificity in lesion detection. R-CNNs show the potential to improve the sensitivity and specificity of lesion recognition, notably in medical imaging tasks like recognizing lesions in diabetic retinopathy. R-CNNs also provide a complex framework that combines the strengths of CNNs and RNNs, allowing for more extensive medical image processing and improved lesion identification accuracy. One of the key benefits of employing R-CNNs for lesion diagnosis is their capacity to extract both local and global contextual information from medical images. CNNs use the CL to extract the hierarchical characteristics from the image patches, allowing them to detect the possible lesion sites (Wang and Lo, 2018). However, by including the recurrent layers, R-CNNs may analyze sequences of the image patches or frames, collecting temporal connections and contextual information from many geographical locations. This sequential processing allows the R-CNNs to better discriminate minor alterations in lesion features from background noise, increasing the sensitivity in lesion identification. R-CNNs could modify their focus to the different regions of interest in the medical images, resulting in a greater specificity in lesion detection. R-CNNs may successfully distinguish genuine lesions from artifacts or benign structures by iteratively refining feature representations in both spatial and temporal dimensions (Nur-A-Alam *et al.*, 2023). This flexibility

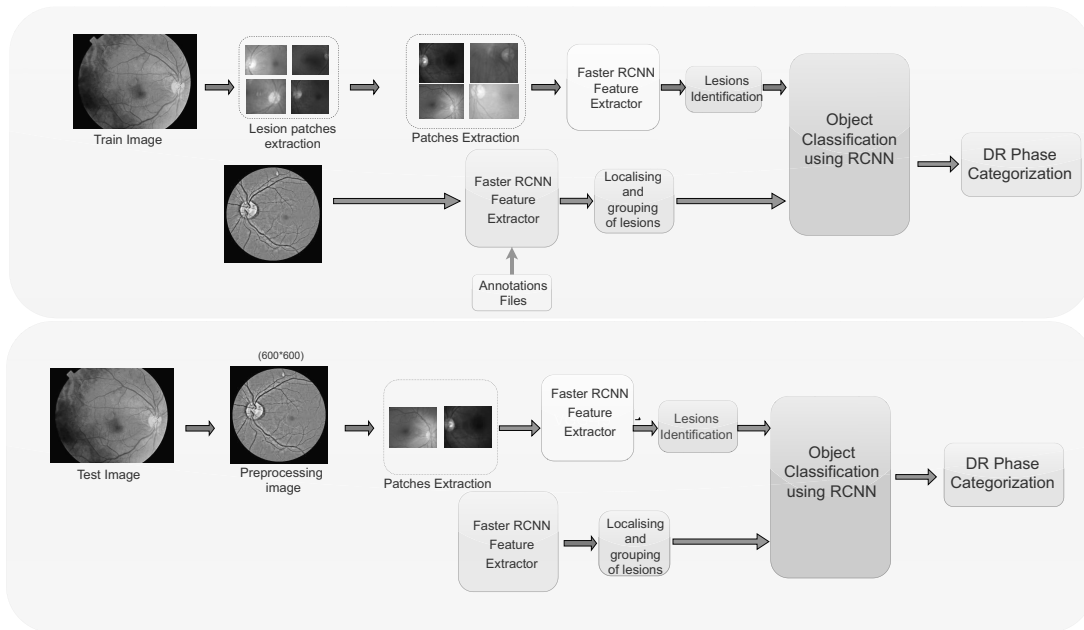


Fig. 5. Diabetic retinopathy lesion detection.

enables the R-CNNs to minimize the false positives and enhances the lesion detection precision, lowering the risk of misdiagnosis and wasteful treatments.

The rectified linear unit (ReLU) function is used as the main activation function in the current study due to its non-saturated qualities, which assist in reducing the vanishing gradient problem that is typically experienced with other activation functions such as the hyperbolic tangent and sigmoid ones. ReLU's effectiveness and simplicity are among its main points of favor. The gradient is one when the input is positive, ensuring that the gradients do not get smaller as they move through the layers. Compared with saturated functions like the hyperbolic tangent and sigmoid, which may squash the input into a limited range, resulting in very tiny gradients and sluggish learning, this leads to quicker and more efficient training. ReLU also adds a sparsity to the network by producing zero for every negative input value. As fewer neurons fire at the same time, sparsity can improve the model's capacity to generalize by lowering the risk of overfitting. ReLU is also computationally efficient, enabling quicker training and inference times due to its computational simplicity—it only requires a threshold operation.

Based on merging the strengths of RNNs and CNNs, the results show that the R-CNNs can extract both local and global contextual information from images. This combination allows R-CNNs to evaluate the image patch sequences, gathering temporal correlations and spatial data, which enhances the ability to identify real lesions while reducing false positives. The paper demonstrates

how this periodic upgrading of the feature representations allows R-CNNs to efficiently discern between benign structures and actual lesions by focusing on the important regions. Because of this, R-CNNs have enhanced lesion detection sensitivity and specificity, reducing the likelihood of inaccurate diagnoses and unnecessary treatments and resulting in more accurate and efficient healthcare.

4. Results and discussion

In the section the experimental results of the suggested DR classification model are presented. The primary objective of this research is to improve the quality of images so that better classification results could be obtained by removing noise, recognizing blood vessels, and detecting the optic disc. In addition, the process encompasses the extraction of exudates and microaneurysms alongside the classification of various manifestations of diabetic retinopathy into distinct categories: mild, moderate, severe NPDR, and proliferative diabetic retinopathy (PDR). After preparing the data, the images are partitioned into distinct categories for training and assessment purposes. Then, the R-CNN model is supplied with the training data.

4.1. Dataset characteristics and preprocessing. The proposed DR model has an input image with a size of 227×227 pixels, which is processed. A total of 51,529 features are extracted using the GLCM, and a total of 82 features are considered for further processing with a

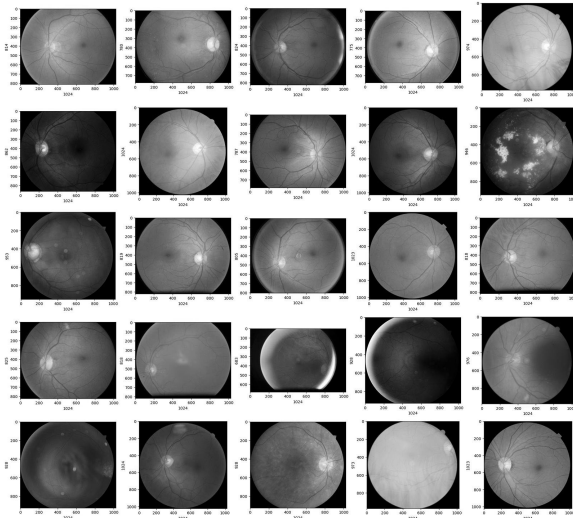


Fig. 6. Diabetic retinopathy phases (from left to right): no DR, mild DR, moderate DR, severe, proliferative DR.

learning rate of 0.01. The extracted features are used to train the R-CNN model. Five convolutional, two fully linked, and one binary classification layer make up the R-CNN, which was designed to rate the quality of images automatically. The CL kernel sizes and strides are as follows: The first CL has 96 kernels of size 11×11 with a stride of 4. The second CL has 256 kernels of size 5×5 with a stride of 1. The third CL contains 384 kernels of size 3×3 with a stride of 1. The fourth CL consists of 384 kernels of size 3×3 with a stride of 1. The fifth CL has 256 kernels of size 3×3 with a stride of 1. Two fully connected layers with an activation size of 4096 neurons follow these convolutional network layers. As a result, the completely linked layer's final output yielded a 4096-dimensional image, as depicted in Fig. 6.

4.2. Activation function. Considering a parameter or state of the input, activation functions in deep learning specify the output of a neuron. The model can learn from complicated data according to the nonlinear features they incorporate into the network's learning mechanism. R-CNNs commonly use the activation layers with sigmoid, Tanh, ReLU, LeakyReLU, and softmax functions. Saturated and nonsaturated activation layers are two different categories for the activation layers. The output of the activation layer is categorized as saturated if it lies between finite bounds; alternatively, if it trends toward infinity, it is regarded as a nonsaturated activation function. Unlike saturated activation layers, nonsaturated activation functions have several advantages.

4.2.1. Sigmoid function. It is a logistic function with a range of $(0, 1)$. It is typically applied to

binary classification problems, although back-propagation encounters the vanishing gradients problem. It is defined as

$$f(y) = \frac{1}{1 + e^{-y}}. \quad (6)$$

4.2.2. Tanh function. The hyperbolic tangent function is frequently employed when a negative gradient, a saturated activation layer, is crucial. This function is much like to the sigmoid function, but produces results in a range $(-1, 1)$

$$f(y) = \frac{e^y - e^{-y}}{e^y + e^{-y}}. \quad (7)$$

4.2.3. Rectified linear unit (ReLU) function. A leaky rectified linear activation layer is a nonsaturated activation function. It attempts to fix the failing ReLU issue called dying ReLU. When the input is less than zero, minor negative values are permitted. The leaky ReLU function is defined as

$$f(y) \begin{cases} = y & \text{if } y > 0, \\ \propto y & \text{if } y < 0. \end{cases} \quad (8)$$

4.2.4. Softmax function. Softmax is an activation layer that creates a discrete probability distribution vector and is often near the end of a network. The softmax function is represented by

$$p(z = i|Y) = \frac{e^{y^T w_i}}{\sum_{m=1}^M e^{y^T w_m}}, \quad (9)$$

where Y is the input vector and w_i is the predicted probability of $z = i$.

4.3. Convolution layer architecture. The layered architecture in diabetic retinopathy refers to organizing the different structural layers found in the retina, which may be affected by diabetic retinopathy. In other words, a CL activates an input by applying a kernel. A feature map that shows the strength of the found features at various locations in the input is produced when the kernel is applied repeatedly to an input. A feature map can be passed via activation functions like ReLU after it has been constructed using several kernels. In a CL, the kernel utilized is smaller than the input data, and the operation carried out between these two objects is often a dot product. Assume an $N \times N$ square neuron component followed by a CL and a kernel of size $s \times s$. The corresponding output of the CL would be $(n - s + 1) \times (n - s + 1)$. To find out the non-linear input to the unit y_{ij}^m , the contributions from the previous layer cells must be summed up,

$$y_{ij}^m = \sum_{p=0}^{l-1} \sum_{q=0}^{l-1} x_{(i+p)(j+q)}^{m-1}. \quad (10)$$

The CL applies the assessed nonlinearity as given by

$$x_{ij}^m = \lambda(y_{ij}^m). \tag{11}$$

4.4. Pooling layer. The two key variables in the pooling layers are the size of the kernel being used and the stride. The maximum and average pooling layers are the two primary varieties of pooling layers. The maximum value is collected from the image area covered by the pooling kernel in CNN. The kernel is typically 2×2 in size, however it might change depending on the situation. This is accomplished by shrinking the size of the convolved feature (the CL's output), as

$$f_{MP}(Y) = \max_{p,q}(p, q). \tag{12}$$

4.5. Performance analysis along phases.

4.5.1. MultiClass confusion matrix. A confusion matrix, or an error matrix, is a standardized evaluation parameter that is used with machine intelligence models. It is a specific table layout that allows visualizing the correctly predicted samples out of the evaluation. The confusion matrix has four main components:

- True positive (TPv): These are the occurrences that the categorization model properly predicted as positive.
- True negative (TNv): True negative cases are those that are accurately predicted by the categorization model.
- False positive (FPv): The cases are expected to be positive by the model for classification, but the instances are negative.
- False negative (FNv): True positives that the classification model wrongly projected as negatives.

A multiclass confusion matrix evaluates a model's ability to discriminate between several phases or classes of DR, as shown in Fig. 7. This matrix organizes the model's predictions for all classes and compares them with the ground truth labels. This helps in finding the performance metrics of various classes in DR.

4.5.2. Model performance comparison. Performance assessment is a vital aspect of the deep learning process (Bhandari et al., 2022). Following the classification, the model's efficacy is measured using key metrics, including accuracy, recall, precision, and the F1-score, as shown in Table 2. To assess the effectiveness of the proposed system, a comparative analysis is conducted to evaluate its accuracy with other CNN models used for feature extraction, as shown in Fig. 8. In deep learning, accuracy,

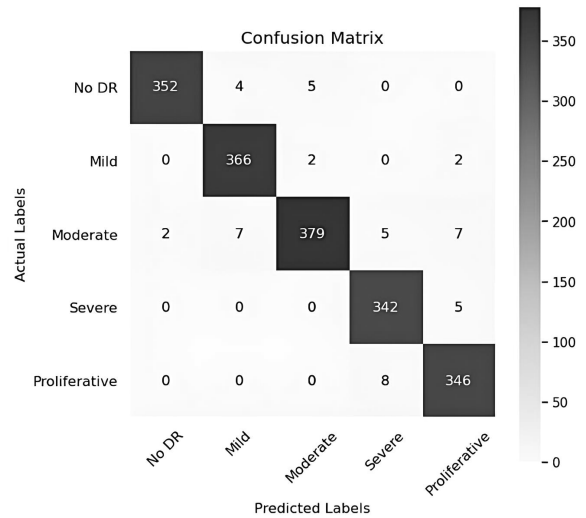


Fig. 7. Confusion matrix of diabetic retinopathy phases.

and loss graphs are critical visualizations for monitoring a model's performance during training and assessment. These graphs show how effectively the model is learning from the data and how its performance varies over time as shown in Figs. 9 and 10.

Table 3 compares the attributes of the proposed system concerning several models used for classification purposes.

4.6. Practical implications. The described model, which uses an R-CNN to determine DR, is linked to a mobile application that makes it intuitive for clinicians and patients to categorize illnesses based on the image supplied as input. Figure 11 represents the architecture of the proposed system. Images of the affected region are to be captured by the mobile application, and the information is to be securely saved on a remote server via the representational state transfer (REST) API. MongoDB handles enormous volumes of user data by using NoSQL as shown in Fig. 11.

Mobile-based data access applications can benefit from the compatibility and flexibility of the Flutter framework. By including the R-CNN capabilities into the model, Flutter's abundance of libraries makes it appropriate for deploying deep learning models. For apps that need to analyze data in real time, Flutter's native performance guarantees seamless and intuitive user experiences. Its vast widget library makes it possible for developers to design complex yet user-friendly ML integrated user interfaces that improve engagement and usability. Additionally, it allows developers to implement ML models that spur innovation and improve how users interact. Besides, Tensorflow libraries allow for the import of the R-CNN, which guarantees a smooth integration and

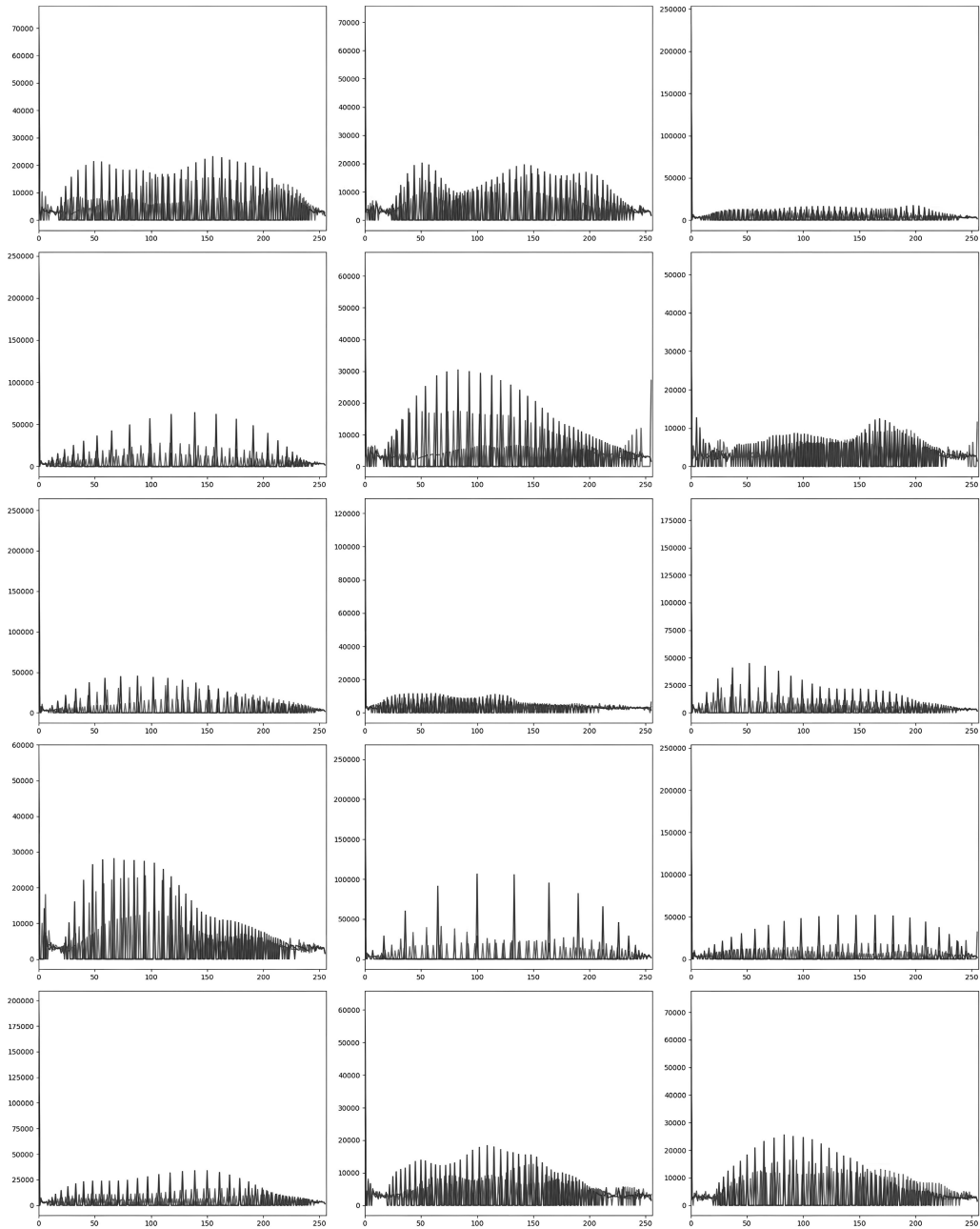


Fig. 8. Outcome of diabetic retinopathy.

Table 2. Performance analysis of the proposed model.

Phases	Accuracy	Precision	Recall	F1-score
No DR	0.92	0.99	0.98	0.97
Mild	0.96	0.96	0.99	0.98
Moderate	0.983	0.98	0.95	0.96
Severe	0.97	0.96	0.99	0.97
Proliferative	0.95	0.97	0.98	0.97

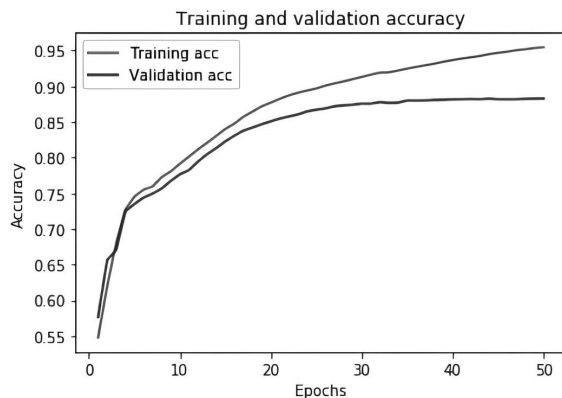


Fig. 9. Training and validation accuracy.

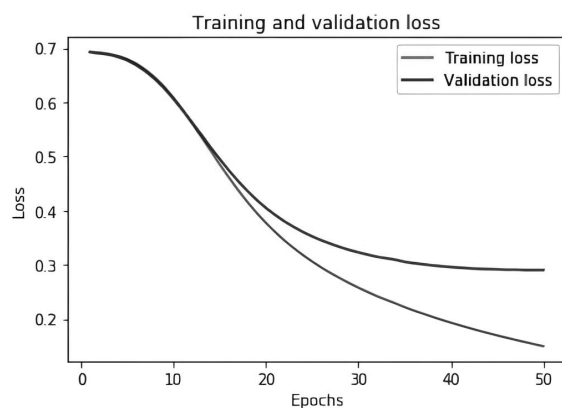


Fig. 10. Training and validation loss.

enables the use of TensorFlow advanced machine learning capabilities.

Patients can effortlessly capture retinal images using their mobile devices, which are then used as input for the interface. The interface then uses the R-CNN to handle data preprocessing. The iOS platform can easily incorporate R-CNN implementation. Effective interactions can be facilitated by using XML/JSON formats for information flow between the interface and R-CNN. Additionally, MongoDB may be used as the backend database solution, offering an adaptable and scalable storage architecture for the management of image records and patient data. A flexible and efficient method for categorizing different sorts of emergency recovery is demonstrated by the model's use of an R-CNN inside an IOS platform architecture, in conjunction with the integration of a MongoDB database and the adaptability of Flutter for cross-platform development. This integration has the potential to improve patient outcomes in the management of the DR by enhancing diagnosis, encouraging early action, and so on. The corresponding screenshots are shown in Figs. 12 and 13.

The adaptable way to store the user-uploaded DL model images and make it easier for the DL model to extract them is to utilize MongoDB. This document-based paradigm is more suited for storing images since it can hold complicated data. Images uploaded by users can be stored by MongoDB together with pertinent information like the user ID, timestamp, and other details. This facilitates the effective storage and retrieval of images. As a result, DL models may access the input data required for activities like inference and training.

5. Conclusion

Implementing a DR detection system using the region CNN models shows excellent performance in identifying and categorizing DR. They can recognize the DR symptoms, including microaneurysms, exudates, and hemorrhages, with accuracy. The need for manual screening is diminished when the R-CNN models are used to save considerable time and resources. R-CNN models are used to diagnose the DR and demonstrate the strong potential of artificial intelligence in illness detection and medical imaging, pointing to a prospective transition towards automated, noninvasive diagnostic methods. The R-CNN proves its effectiveness in precisely detecting the DR severity levels thorough model training and rigorous testing. It has also drawn attention to the need for more varied data to successfully train these models. The quality and variety of the training data can impact these models' performance.

Considering the encouraging results, an additional study is necessary to improve the technology and make it more dependable and durable. It is also necessary to handle ethical issues like patient privacy and model transparency. The creation of an intuitive mobile application interface makes DR screening more accessible and enables people with diabetes to effortlessly monitor their eye health from their mobile devices. This strategy facilitates prompt treatments and proactive healthcare management, which eventually lessens the burden of DR-related visual losses. The potential for technology-driven solutions to solve complicated healthcare concerns is explored via the practical implementation of this system.

Due to the high computational resource requirements of the R-CNN models, healthcare institutions with limited high-performance computer equipment may find it difficult to implement these sophisticated diagnostic tools widely. While the R-CNN models save time and money by eliminating the need for manual screening, they are not perfect. False positives and false negatives can still happen and, therefore, human oversight and strong validation are still necessary to guarantee diagnostic accuracy. Additionally, ethical issues including the patient privacy, data security, and AI model transparency

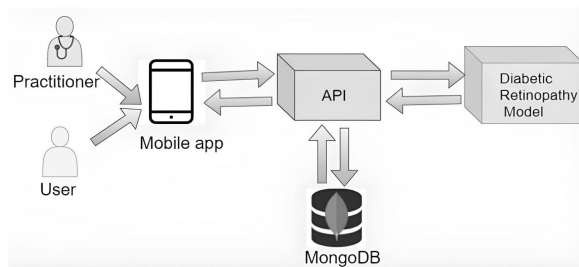


Fig. 11. Framework of the proposed mobile application.

Table 3. Accuracies produced by different classifiers.

Techniques	Accuracy
MLP+ BR (Harun <i>et al.</i> , 2019)	72.11
SVM + NN (Kandan and Aruna, 2012)	89.60
DNN (Alyoubi <i>et al.</i> , 2020)	95.80
RESNET 50 (Li <i>et al.</i> , 2020)	92.60
VGG-19 (Sudha and Ganeshbabu, 2021)	96.00
R-CNN	98.38

may arise. Handling patient data carefully and creating transparent models is necessary to win over patients' and healthcare professionals' confidence. Furthermore, whereas mobile apps for DR screening increases accessibility and convenience, variations in image quality may occur due to different mobile device cameras and lighting conditions.

6. Future research

The future of diabetic retinopathy research holds an enormous promise for ground-breaking advances in diagnosis, treatment, and management techniques. Advances in imaging technologies, such as hyperspectral imaging and optical coherence tomography (OCT), promise to give unique insights into the structural and functional changes in the retina, allowing for earlier identification and, more precisely, monitoring of the disease development. Furthermore, incorporating artificial intelligence and machine learning algorithms opens the possibility of automated, accurate, and scalable diagnostic systems that can transform the DR screening and patient care delivery.

Personalized medicine techniques, customized to specific patient features and genetic profiles, can improve therapeutic efficacy while reducing side effects. Furthermore, the growth of telemedicine and remote monitoring of the technologies creates an opportunity to increase access to DR screening and follow-up care, particularly in poor populations area. As the research uncovers, the new biomarkers and treatment targets, developing a combination of medications and tailored interventions shows promise for improving

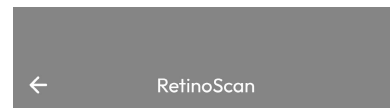

patient outcomes and maintaining a vision. Addressing issues such as patient education, adherence to treatment regimens, and global health inequities will be critical in providing equitable access to effective care for everyone impacted by DR globally. By embracing interdisciplinary partnerships, using technology breakthroughs, and prioritizing patient-centered methods, the future of DR research holds a significant promise for expanding our understanding of illness and altering clinical practice to serve patient's needs better.

Acknowledgment

This study is supported via funding from Prince Sattam bin Abdulaziz University (project no. PSAU/2024/R/1445).

References

- Albahli, S., Nazir, T., Irtaza, A. and Javed, A. (2021). Recognition and detection of diabetic retinopathy using Densenet-65 based Faster-R-CNN, *Computers, Materials & Continua* **67**(2): 1333–1351.
- Alwakid, G., Gouda, W. and Humayun, M. (2023). Deep learning-based prediction of diabetic retinopathy using CLAHE and ESRGAN for enhancement, *Healthcare* **11**(6).
- Alyoubi, W.L., Shalash, W.M. and Abulhair, M.F. (2020). Diabetic retinopathy detection through deep learning techniques: A review, *Informatics in Medicine Unlocked* **20**(2020): 100377.
- Aziza, E.Z., Mohamed El Amine, L., Mohamed, M. and Abdelhafid, B. (2019). Decision tree CART algorithm for diabetic retinopathy classification, *2019 6th International Conference on Image and Signal Processing and their Applications (ISPA), Mostaganem, Algeria*, pp. 1–5.
- Barburiceanu, S., Terebes, R. and Meza, S. (2021). 3D texture feature extraction and classification using GLCM and LBP-based descriptors, *Applied Sciences* **11**(5): 2332.
- Bergers, G. and Song, S. (2005). The role of pericytes in blood-vessel formation and maintenance, *Neuro-Oncology* **7**(4): 452–464.
- Bhandari, S., Pathak, S. and Jain, S. (2022). A literature review of early-stage diabetic retinopathy detection using deep learning and evolutionary computing techniques, *Archives of Computational Methods in Engineering* **30**(2): 799–810.
- Carrera, E. V., González, A. and Carrera, R. (2017). Automated detection of diabetic retinopathy using SVM, *2017 IEEE XXIV International Conference on Electronics, Electrical Engineering and Computing (INTERCON), Cusco, Peru*, pp. 1–4.
- Das, D., Biswas, S. and Bandyopadhyay, S. (2022). Detection of diabetic retinopathy using convolutional neural networks for feature extraction and classification (DRFEC), *Multi-media Tools and Applications* **82**(19): 1–59.



Patient Name

Patient ID

Upload the Scan

Stage*: Not a Diabetic Retinopathy

Confidence Level: 93%

DISCLAIMER: This software is in beta, and results may include false positives. The displayed outcomes are preliminary assessments and may differ from actual facts on the ground.



Fig. 12. Screenshot from the mobile application.

Fig. 13. Another screenshot from the mobile application.

- Fayyaz, A.M., Sharif, M.I., Azam, S., Karim, A. and El-Den, J. (2023). Analysis of diabetic retinopathy (DR) based on the deep learning, *Information* **14**(1): 30.
- Guleria, P., Naga Srinivasu, P. and Hassaballah, M. (2023). Diabetes prediction using Shapley additive explanations and DSaaS over machine learning classifiers: A novel healthcare paradigm, *Multimedia Tools and Applications* **83**: 40677–40712.
- Gupta, A. and Chhikara, R. (2018). Diabetic retinopathy: Present and past, *Procedia Computer Science* **132**(2018): 1432–1440.
- Harun, N.H., Yusof, Y., Hassan, F. and Embong, Z. (2019). Classification of fundus images for diabetic retinopathy using artificial neural network, *2019 IEEE Jordan International Joint Conference on Electrical Engineering and Information Technology (JEEIT), Amman, Jordan*, pp. 498–501.
- Hinton, G.E., Srivastava, N., Krizhevsky, A., Sutskever, I. and Salakhutdinov, R.R. (2012). Improving neural networks by preventing co-adaptation of feature detectors *arXiv*: 1207.0580.
- IDF (2024). *IDF Diabetes Atlas, 8th Edition*, International Diabetes Federation, Brussels, <https://diabetesatlas.org/>.
- Kandan, R. and Aruna, P. (2012). SVM and neural network based diagnosis of diabetic retinopathy, *International Journal of Computer Applications* **41**(1): 6–12.
- Kandel, I. and Castelli, M. (2020). Transfer learning with convolutional neural networks for diabetic retinopathy image classification. A review, *Applied Sciences* **10**(6): 1–24.
- Kaur, J. and Kaur, P. (2022). Automated computer-aided diagnosis of diabetic retinopathy based on segmentation and classification using K-nearest neighbor algorithm in retinal images, *The Computer Journal* **66**(8): 2011–2032.
- Li, X., Hu, X., Yu, L., Zhu, L., Fu, C.-W. and Heng, P.-A. (2020). CANet: Cross-disease attention network for joint diabetic retinopathy and diabetic macular edema grading, *IEEE Transactions on Medical Imaging* **39**(5): 1483–1493.
- Liu, C., Ge, H.-M., Liu, B.-H., Dong, R., Shan, K., Chen, X., Yao, M.-D., Li, X.-M., Yao, J., Zhou, R.-M., Zhang, S.-J., Zhao, C. and Yan, B. (2019). Targeting pericyte–endothelial cell crosstalk by circular RNA-cPWWP2A inhibition aggravates diabetes-induced microvascular dysfunction, *Proceedings of the National Academy of Sciences* **116**: 7455–7464.
- Mohanty, C., Mahapatra, S., Acharya, B., Kokkoras, F., Gerogiannis, V.C., Karamitsos, I. and Kanavos, A. (2023). Using deep learning architectures for detection

- and classification of diabetic retinopathy, *Sensors* **23**(12): 1–18.
- Naga Srinivasu, P., Ijaz, M.F. and Woźniak, M. (2024). XAI-driven model for crop recommender system for use in precision agriculture, *Computational Intelligence* **40**(1): e12629.
- Nur-A-Alam, M., Nasir, M.M.K., Ahsan, M., Based, M.A., Haider, J. and Palani, S. (2023). A faster R-CNN-based diabetic retinopathy detection method using fused features from retina images, *IEEE Access* **11**: 124331–124349.
- Oh, K., Kang, H., Leem, D., Lee, H., Seo, K.Y. and Yoon, S. (2021). Early detection of diabetic retinopathy based on deep learning and ultra-wide-field fundus images, *Scientific Reports* **11**: 1–9.
- Patel, S.N., Shi, A., Wibbelsman, T.D. and Klufas, M.A. (2020). Ultra-widefield retinal imaging: An update on recent advances, *Therapeutic Advances in Ophthalmology* **12**: 2515841419899495.
- Priyadharsini, C. and Jagadeesh Kannan, R. (2023). Retinal image enhancement based on color dominance of image, *Scientific Reports* **13**: 7172.
- Rajesh, A.E., Davidson, O.Q., Lee, C.S. and Lee, A.Y. (2023). Artificial intelligence and diabetic retinopathy: AI framework, prospective studies, head-to-head validation, and cost-effectiveness, *Diabetes Care* **46**(10): 1728–1739.
- Rakshitha, T.R., Devaraj, D. and Kumar, S.C.P. (2016). Comparative study of imaging transforms on diabetic retinopathy images, *2016 IEEE International Conference on Recent Trends in Electronics, Information and Communication Technology (RTEICT), Bangalore, India* pp. 118–122.
- Ramanathan, R.S. (2017). Correlation of duration, hypertension and glycemic control with microvascular complications of diabetes mellitus at a tertiary care hospital, *Integrative Molecular Medicine* **4**(4): 1–4.
- Ren, S., He, K., Girshick, R. and Sun, J. (2017). Faster r-CNN: Towards real-time object detection with region proposal networks, *IEEE Transactions on Pattern Analysis and Machine Intelligence* **39**(6): 1137–1149.
- Romeo, G., Liu, W.-H., Asnaghi, V., Kern, T.S. and Lorenzi, M. (2002). Activation of nuclear factor κB induced by diabetes and high glucose regulates a proapoptotic program in retinal pericytes, *Diabetes* **51**(7): 2241–2248.
- Romero-Aroca, P., Baget-Bernaldiz, M., Pareja-Rios, A., Lopez-Galvez, M., Navarro-Gil, R. and Verges, R. (2016). Diabetic macular edema pathophysiology: Vasogenic versus inflammatory, *Journal of Diabetes Research* **2016**(1): 1–17.
- Sakthi Sree Devi, M., Ramkumar, S., Vinuraj Kumar, S. and Sasi, G. (2021). Detection of diabetic retinopathy using OCT image, *Materials Today: Proceedings* **47**: 185–190.
- Sebastian, A., Elharrouss, O., Al-Maadeed, S. and Almaadeed, N. (2023). A survey on deep-learning-based diabetic retinopathy classification, *Diagnostics* **13**(3): 1–22.
- Solomon, S.D., Chew, E., Duh, E.J., Sobrin, L., Sun, J.K., VanderBeek, B.L., Wyckoff, C.C. and Gardner, T.W. (2017). Diabetic retinopathy: A position statement by the American Diabetes Association, *Diabetes Care* **40**(3): 412–418.
- Sorrentino, F.S., Allkabes, M., Salsini, G., Bonifazzi, C. and Perri, P. (2016). The importance of glial cells in the homeostasis of the retinal microenvironment and their pivotal role in the course of diabetic retinopathy, *Life Sciences* **162**: 54–59.
- Tomita, Y., Lee, D., Tsubota, K., Negishi, K. and Kurihara, T. (2021). Updates on the current treatments for diabetic retinopathy and possibility of future oral therapy, *Journal of Clinical Medicine* **10**(20): 1–19.
- Sudha, V. and Ganeshbabu, T.R. (2021). A convolutional neural network classifier VGG-19 architecture for lesion detection and grading in diabetic retinopathy based on deep learning, *Computers, Materials & Continua* **66**(1): 827–842.
- Vankadaru, V., Penugonda, G., Parvathaneni, N. and Bhoi, A.K. (2023). Heart failure prediction using radial basis with metaheuristic optimization, in P. Barsocchi *et al.* (Eds), *Enabling Person-Centric Healthcare Using Ambient Assistive Technology*, Springer, Cham, pp. 129–150.
- Vinayaki, V. and Kalaiselvi, R. (2022). Multithreshold image segmentation technique using remora optimization algorithm for diabetic retinopathy detection from fundus images, *Neural Processing Letters* **54**: 2363–2384.
- Wang, W. and Lo, A.C.Y. (2018). Diabetic retinopathy: Pathophysiology and treatments, *International Journal of Molecular Sciences* **19**(6): 1–14.
- Yasashvini, R., Raja Sarobin, V., Panjanathan, R., J., Yasmine, G. and Anbarasi, J. (2022). Diabetic retinopathy classification using CNN and hybrid deep convolutional neural networks, *Symmetry* **14**(9): 1–13.



Valluri Sri Sravya is a recent graduate with a BS (honors) in computer science and engineering from the Prasad V Potluri Siddhartha Institute of Technology. Her scientific interests are focused on deep learning and its applications.



Parvathaneni Naga Srinivasu is an associate professor at Amrita Vishwa Vidyapeetham in Andhra Pradesh, India. Holding a post-doctoral fellowship from the Department of Teleinformatics Engineering at the Federal University of Ceará, Brazil, he also serves as a research fellow at INTI International University, Malaysia. After graduating in computer science engineering from SSIET, JNTU Kakinada, in 2011, he obtained his MS in computer science technology from GITAM University, Visakhapatnam, in 2013. He also holds a PhD from GITAM University. Doctor Srinivasu's expertise spans biomedical imaging, soft computing, explainable AI, and healthcare informatics.



Jana Shafi is currently affiliated with the Department of Computer Science at Prince Sattam bin Abdulaziz University, Saudi Arabia. She has more than eight years of teaching and research experience. Her scientific interests include online social networks, wearable technology, artificial intelligence, machine learning, deep learning, smart health, and the IoMT.



Waldemar Hołubowski holds an MS degree from the Faculty of Mathematics and Physics, Silesian University of Technology, Gliwice, Poland, and received his PhD and DSc degrees in mathematics from Saint Petersburg State University, Russia, in 1991 and 2008, respectively. He had been a visiting researcher with the University of Manitoba, Canada, and the Euler Institute, St. Petersburg, Russia. He is currently the head of the Faculty of Applied Mathematics, Silesian University of Technology. His research interests include the theory of groups and Lie algebras, matrix theory and their applications in engineering.



Adam Zielonka received his MS degree in mathematics and his PhD degree in mechanical engineering from the Silesian University of Technology, Gliwice, Poland, in 2001 and 2007, respectively. He is an assistant professor with the Faculty of Applied Mathematics there. He has authored/coauthored over 50 research papers in international conferences and journals in the area of applied computing. He works on numerical methods, particularly, by applying computational intelligence, swarm intelligence algorithms, and smart environments for the Internet of things.

Received: 18 April 2024

Revised: 14 June 2024

Accepted: 23 August 2024